



PRESENTING CLINICAL SIGNS

DATE History: New murmur. Recently diagnosed with diabetes. Previously diagnosed with IBD.

ECHOCARDIOGRAPHIC FINDINGS

3/24/23 2D, M-mode, and Doppler study.

PERFORMED BY: There is mild left atrial dilation. The mitral valve leaflets are mildly thickened and exhibit systolic prolapse. There is Doppler evidence of mitral regurgitation present. There is mild left ventricular dilation. Left ventricular systolic function is normal. The aorta and aortic valve are normal. Right atrial and right ventricular dimensions are normal. The tricuspid valve is normal. The pulmonary artery and pulmonic valve are normal. No shunting lesions are visualized. No heartworms are visualized. No pericardial effusion or cardiac masses are seen.

Dr. Meredith Swart

INTERPRETED BY

Keith Blass, DVM,
MS, DACVIM
(Cardiology)

LA - 24.6 mm
LVIDd - 25.8 mm
LVIDs - 16.5 mm
FS - 36%
LVOT - 0.62 m/s
RVOT - 0.65 m/s

PATIENT

Pete Crouse

ASSESSMENT/RECOMMENDATIONS

Degenerative mitral valve disease

SPECIES

Canine

This examination demonstrates regurgitation of blood across Pete's mitral valve resulting from degenerative valve disease. Secondary to his regurgitation, Pete has mild dilation of both his left atrium and left ventricle, though his left ventricular systolic function is normal. As only mild left heart chamber dilation is present, Pete's mitral valve disease appears to be well-compensated, and his current risk for the development of clinical signs secondary to it, such as coughing, exercise intolerance, syncope, and labored breathing, appears to be relatively low.

BREED

Chihuahua Mix

I recommend starting Pete on pimobendan (1.25 mg BID), as this medication should help to slow the progression of his mitral valve disease.

SEX

A recheck echocardiogram is recommended in 9 months to monitor for disease progression. Thoracic radiographs are recommended if Pete experiences respiratory clinical signs.

MN

AGE

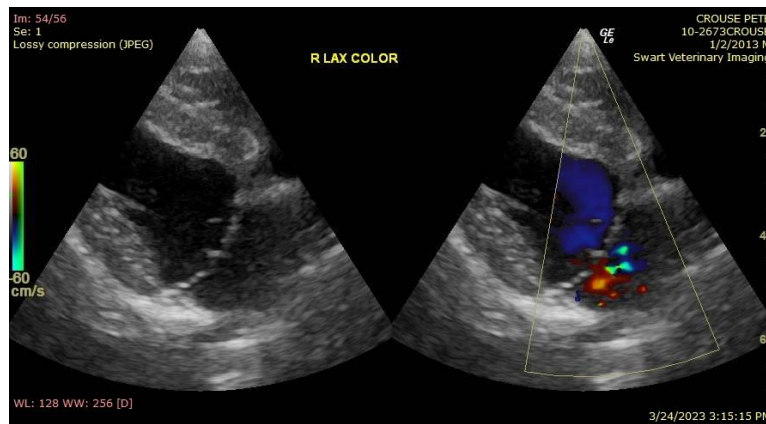
10 y

WEIGHT

8 lb

HOSPITAL NAME

Swart Veterinary
Imaging



REFERRING VET

Dr. Swart

The information and recommendations provided are based on the images presented by the



DATE referring veterinarian. No evaluation can be communicated regarding pathology that was not visible in the image/video clips provided.

3/24/23 Thank you for this referral. If the clinical or image interpretation does not parallel your findings or if I can be of any further assistance please contact me.

PERFORMED BY: Keith Blass, DVM, MS, DACVIM (Cardiology)
KeithBlass@gmail.com
631-804-5754

INTERPRETED BY

Keith Blass, DVM,
MS, DACVIM
(Cardiology)

PATIENT

Pete Crouse

SPECIES

Canine

BREED

Chihuahua Mix

SEX

MN

AGE

10 y

WEIGHT

8 lb

HOSPITAL NAME

Swart Veterinary
Imaging

REFERRING VET

Dr. Swart